

CLINICAL REPORT

Maxillary and mandibular immediately loaded  
implant-supported interim complete fixed dental prostheses  
on immediately placed dental implants with a digital  
approach: A clinical report



Ryan C. Lewis, DMD,<sup>a</sup> Bryan T. Harris, DMD,<sup>b</sup> Robert Sarno, CDT,<sup>c</sup> Dean Morton, BDS, MS,<sup>d</sup> Daniel R. Llop, CDT,<sup>e</sup>  
and Wei-Shao Lin, DDS<sup>f</sup>

Immediate loading is currently defined as dental implants placed in function earlier than 1 week after implant placement.<sup>1</sup> The immediate loading protocol provides patient-centered benefits of reduced overall treatment time, patient comfort, and postoperative care with predictable clinical outcomes in carefully selected indications.<sup>2,3</sup>

The intraoral conversion procedure using autopolymerizing resin is often used to connect the temporary abutments and the prefabricated interim prostheses templates<sup>4,5</sup> or modified interim complete removable dental prostheses<sup>2,6</sup> for the immediate loading procedure. Although this intraoral conversion technique allows some changes in implant position or angulation compared with that of the presurgical implant plan, it may require more clinical and/or laboratory time during the process.<sup>7</sup> An All-on-4 treatment concept (Nobel Biocare) was proposed to use strategically placed, tilted implants in conjunction with computer-guided surgery and immediately loaded, prefabricated implant-supported interim complete fixed dental prosthesis and to allow rehabilitation of an edentulous jaw with minimal need of bone augmentation.<sup>8-12</sup>

ABSTRACT

This clinical report describes the treatment of maxillary and mandibular immediate implant placement and immediately loaded implant-supported interim complete fixed dental prostheses with a contemporary digital approach. The virtual diagnostic tooth arrangement eliminated the need for a customized radiographic template, and the diagnostic data collection required for computer-guided surgery (digital diagnostic impressions, digital photographs, and a cone beam-computed tomography [CBCT] scan) was completed in a single visit with improved workflow efficiency. Computer-aided design and computer-aided manufacturing (CAD/CAM)-fabricated surgical templates and interim prosthesis templates were made in a dental laboratory to facilitate computer-guided surgery and the immediate loading process. (*J Prosthet Dent* 2015;114:315-322)

Although this approach using a prefabricated prosthesis provides the advantage of reduced clinical and/or laboratory time during the immediate loading process, prosthesis misfit and need for extensive occlusal adjustments were recognized as possible prosthetic complications associated with this technique.<sup>13-15</sup>

In addition to immediate loading, immediate implant placement in the fresh extraction sockets can also provide some patient-centered benefits, including reduced overall treatment time and fewer surgical interventions. When implants were stable at insertion (that is, insertion torque was  $\geq 30$  Ncm) and implant-supported interim complete fixed dental prostheses were used to rigidly connect placed implants, many studies have suggested that immediate loading of immediately placed implants

<sup>a</sup>Resident, Department of Oral Health and Rehabilitation, School of Dentistry, University of Louisville, Louisville, Ky.

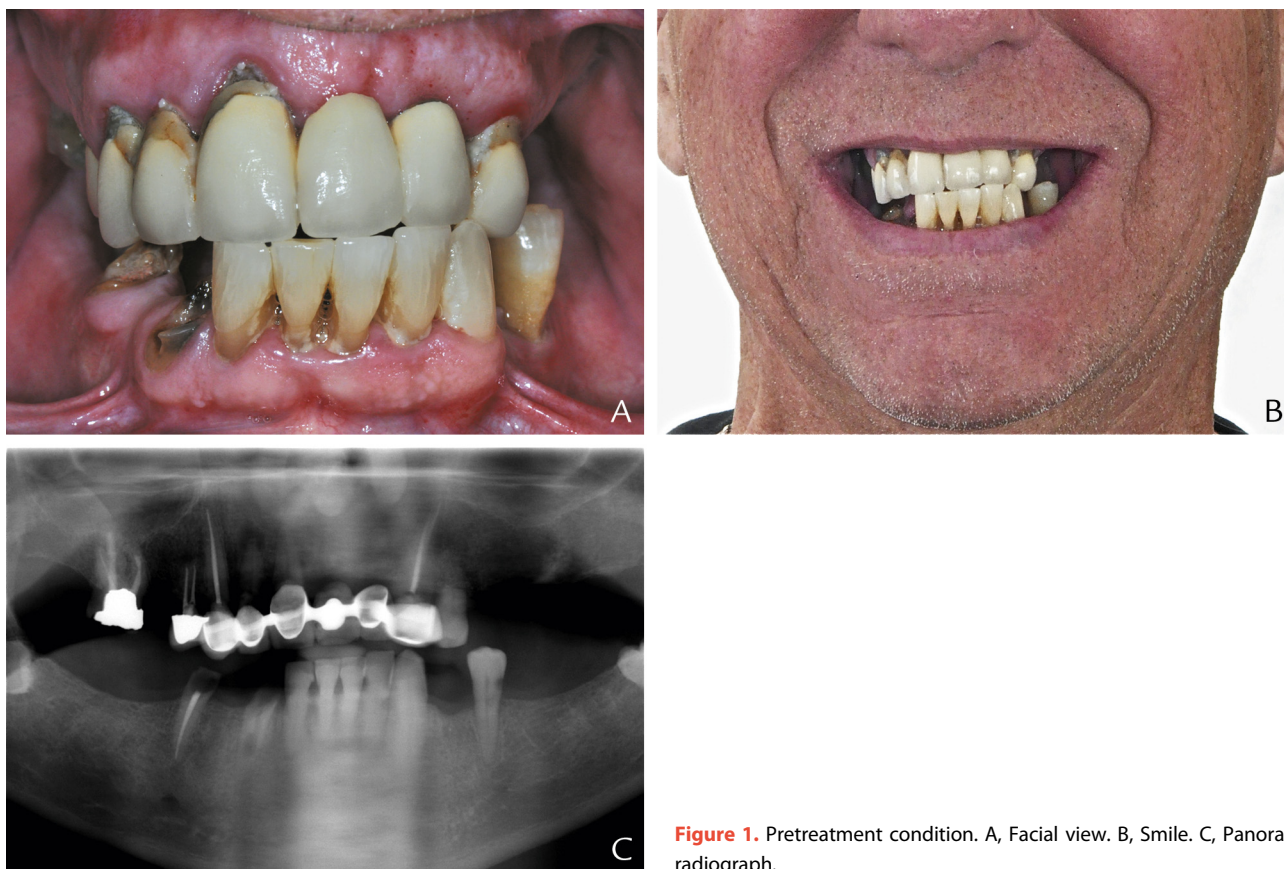
<sup>b</sup>Associate Professor, Department of Oral Health and Rehabilitation, School of Dentistry, University of Louisville, Louisville, Ky.

<sup>c</sup>Certified Dental Technician and Owner, Pinnacle Dental Laboratory Inc, Chesterfield, Mo.

<sup>d</sup>Professor, Department of Oral Health and Rehabilitation, School of Dentistry, University of Louisville, Louisville, Ky.

<sup>e</sup>Founder and President, nSequence, The Center for Advanced Dentistry, Reno, Nev.

<sup>f</sup>Assistant Professor, Department of Oral Health and Rehabilitation, School of Dentistry, University of Louisville, Louisville, Ky.



**Figure 1.** Pretreatment condition. A, Facial view. B, Smile. C, Panoramic radiograph.

in the fresh extraction sockets was a viable option in both the edentulous maxilla and mandible.<sup>16-23</sup>

Based on recent consensus statements, computer-guided implant surgery is defined as the use of a static surgical template that reproduces a virtual implant surgical plan from computerized tomographic data and does not allow the intraoperative modification of implant position.<sup>24</sup> A recent systematic review concluded that computer-guided implant surgery provided a predictable level of accuracy.<sup>25</sup> With development of technology,<sup>26</sup> the Standard Tessellation Language (STL) files resulting from an intraoral digital diagnostic impression and computer-aided design and computer-aided manufacturing (CAD/CAM)-fabricated virtual diagnostic waxing and the Digital Imaging and Communications in Medicine (DICOM) files generated from CBCT scans can be merged in the virtual implant planning software to formulate a prosthetically driven implant surgical plan for subsequent computer-guided implant surgery.<sup>27,28</sup> This process eliminates the need for a customized radiographic template and allows digital diagnostic impression and a CBCT scan to be completed in a single visit; implantation surgery can be performed during the patient's second visit.<sup>29,30</sup>

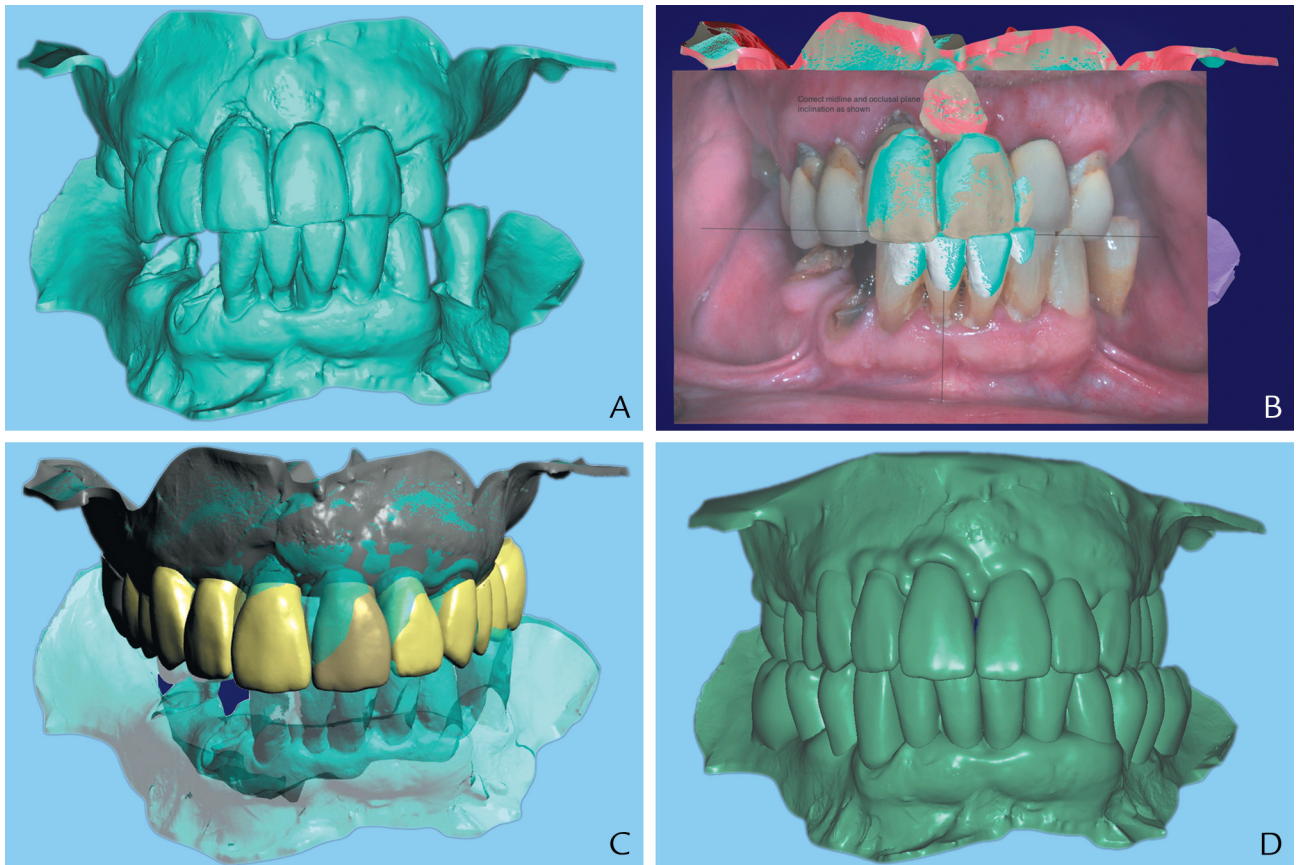
This clinical report describes the treatment of maxillary and mandibular immediate implant placement and

immediately loaded implant-supported interim complete fixed dental prostheses with a contemporary digital approach.

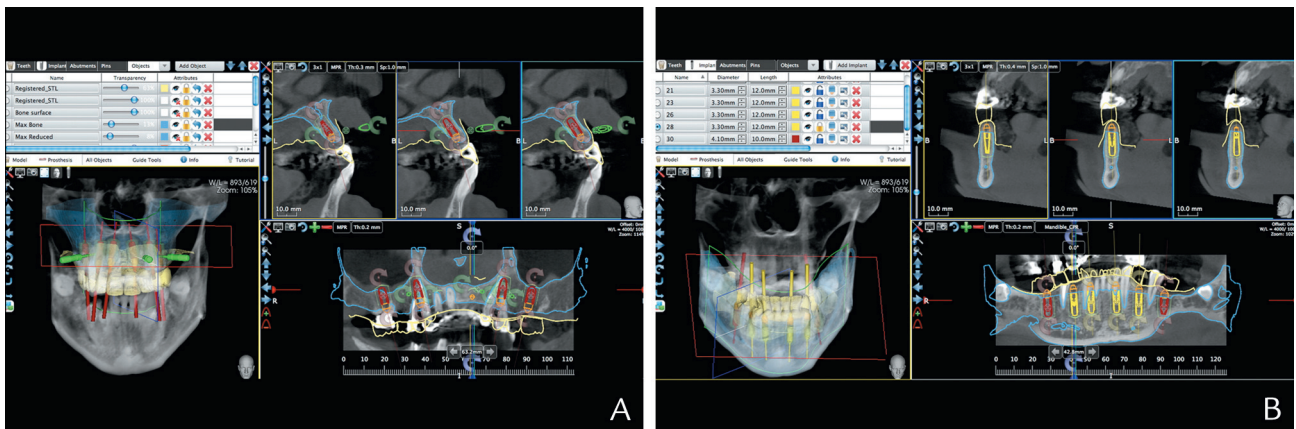
### CLINICAL REPORT

A 70-year-old white man presented with a partially edentulous maxilla and mandible and the wish to restore the missing and broken teeth. Clinical and radiographic examination (Fig. 1) revealed chronic generalized moderate periodontitis, a canted occlusal plane, occlusion disharmony, extrusion of remaining mandibular anterior teeth, recurrent dental caries around the existing fixed dental prostheses, and need for endodontic retreatment on multiple teeth. Different treatment alternatives were discussed with the patient, who consented to the treatment plan with maxillary and mandibular implant-supported complete fixed dental prostheses. The patient agreed to simultaneous maxillary and mandibular immediate implant placement with computer-guided surgery and immediately loaded implant-supported interim complete fixed dental prostheses.

An intraoral digital scanner (Cadent iTero; Align Technology Inc) was used to make the digital diagnostic impressions with an interocclusal registration (Fig. 2A).



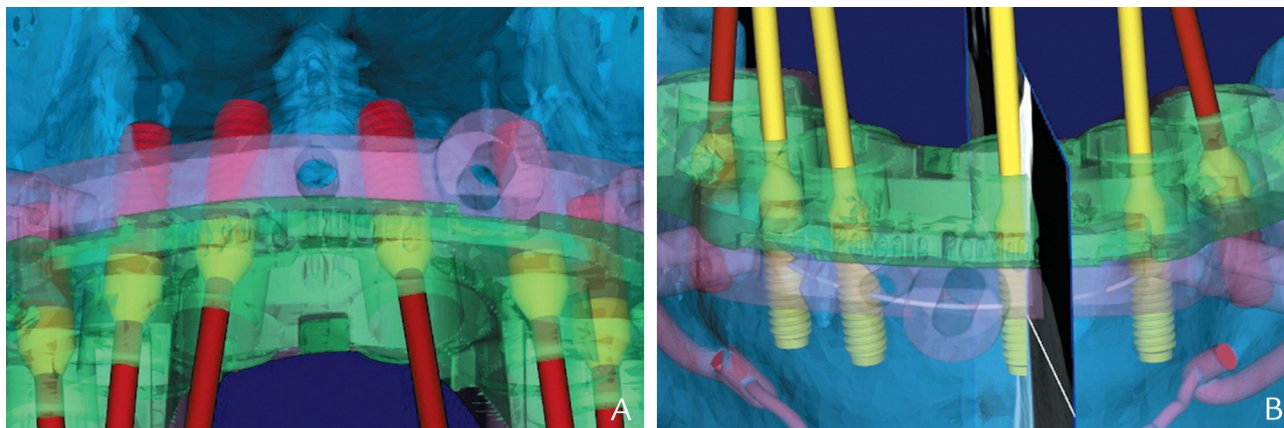
**Figure 2.** A, Digital diagnostic impression. B, Clinical digital photographs overlapped with digital diagnostic impressions for additional information in subsequent virtual diagnostic tooth arrangements. C, Maxillary virtual diagnostic tooth arrangement. D, Complete virtual diagnostic tooth arrangement.



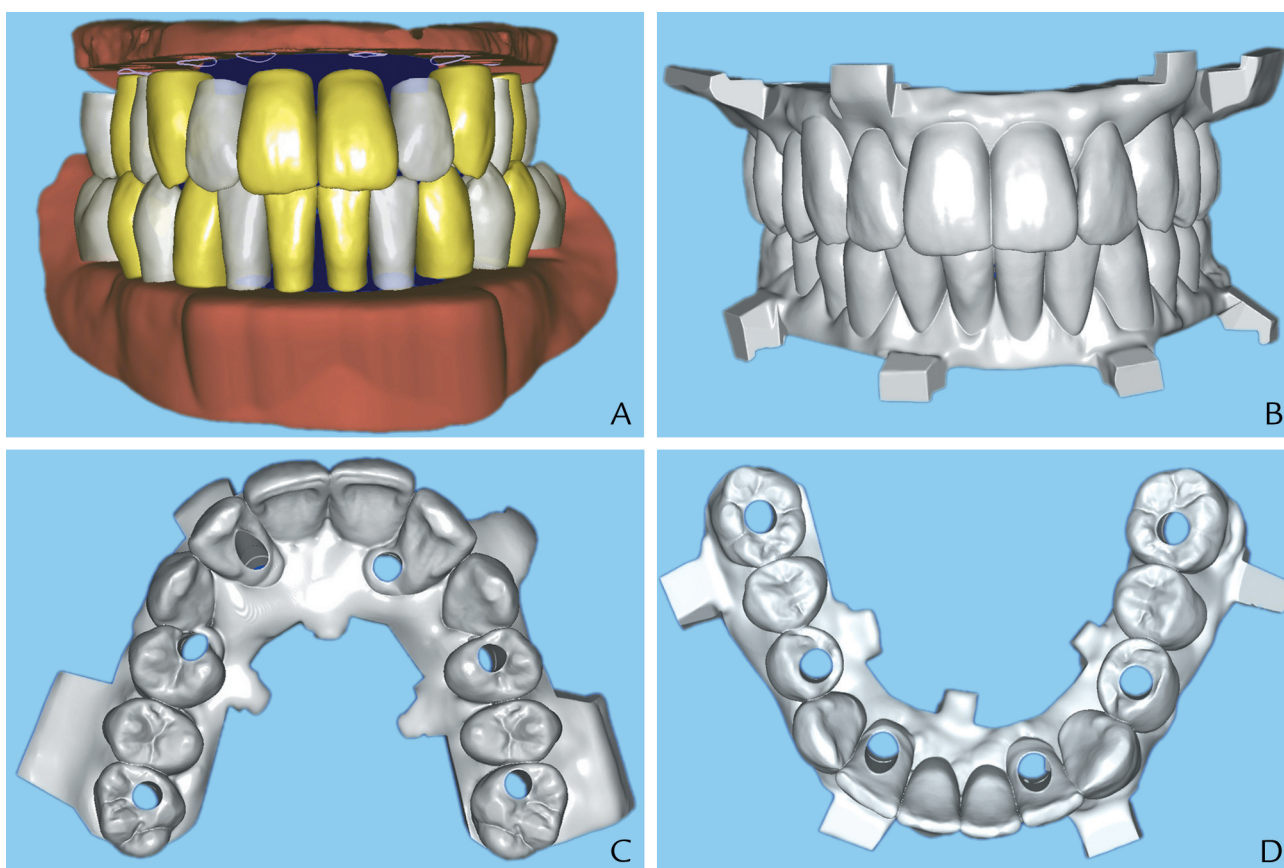
**Figure 3.** Prosthetically driven implant surgical plan. A, Maxillary plan. B, Mandibular plan.

These impressions were forwarded to a dental laboratory (Pinnacle Dental Laboratory Inc) for virtual diagnostic tooth arrangement. Based on results of the clinical examination, the patient’s existing occlusal vertical dimension was deemed acceptable; however, the maxillary midline needed to be shifted toward the left side by 1 mm with correction of the canted occlusal plane. Clinical digital photographs were imported into

CAD/CAM software (Zirkonzahn Modellier; Zirkonzahn) and were overlapped with digital diagnostic impressions to provide the dental technician with supplemental information for subsequent virtual diagnostic tooth arrangement (Fig. 2B). The maxillary virtual diagnostic tooth arrangement was completed first by using the existing dentition as a reference (Fig. 2C). The complete maxillary virtual diagnostic arrangement



**Figure 4.** Two-piece CAD/CAM-fabricated surgical templates. Light purple color represents bone reduction templates with lateral fixation pin access, and light green color represents implant placement templates. Proprietary designs were not included as requested by intellectual property right holders. A, Maxillary templates. B, Mandibular templates. CAD/CAM, computer-aided design/computer-aided manufacture.




**Figure 5.** A, Approved prosthetically-driven implant surgical plan with simulated bone reduction was used to refine virtual diagnostic tooth arrangement. B, Refined virtual diagnostic tooth arrangement retrofitted to bone reduction templates with vertical stops for CAD/CAM-fabricated interim prostheses templates, facial view. C, Occlusal view of maxillary interim prosthesis template. D, Occlusal view of mandibular interim prosthesis template. CAD/CAM, computer-aided design/computer-aided manufacture.

was then used as the antagonist for the mandibular arrangement.

A CBCT scan (3D Accutomo 170; J. Morita USA) of the maxillary and mandibular arches was completed for

preoperative assessment. The STL files from the intraoral digital diagnostic impression, the virtual diagnostic tooth arrangement (Fig. 2D), and the DICOM files generated from the CBCT scans were merged with virtual implant



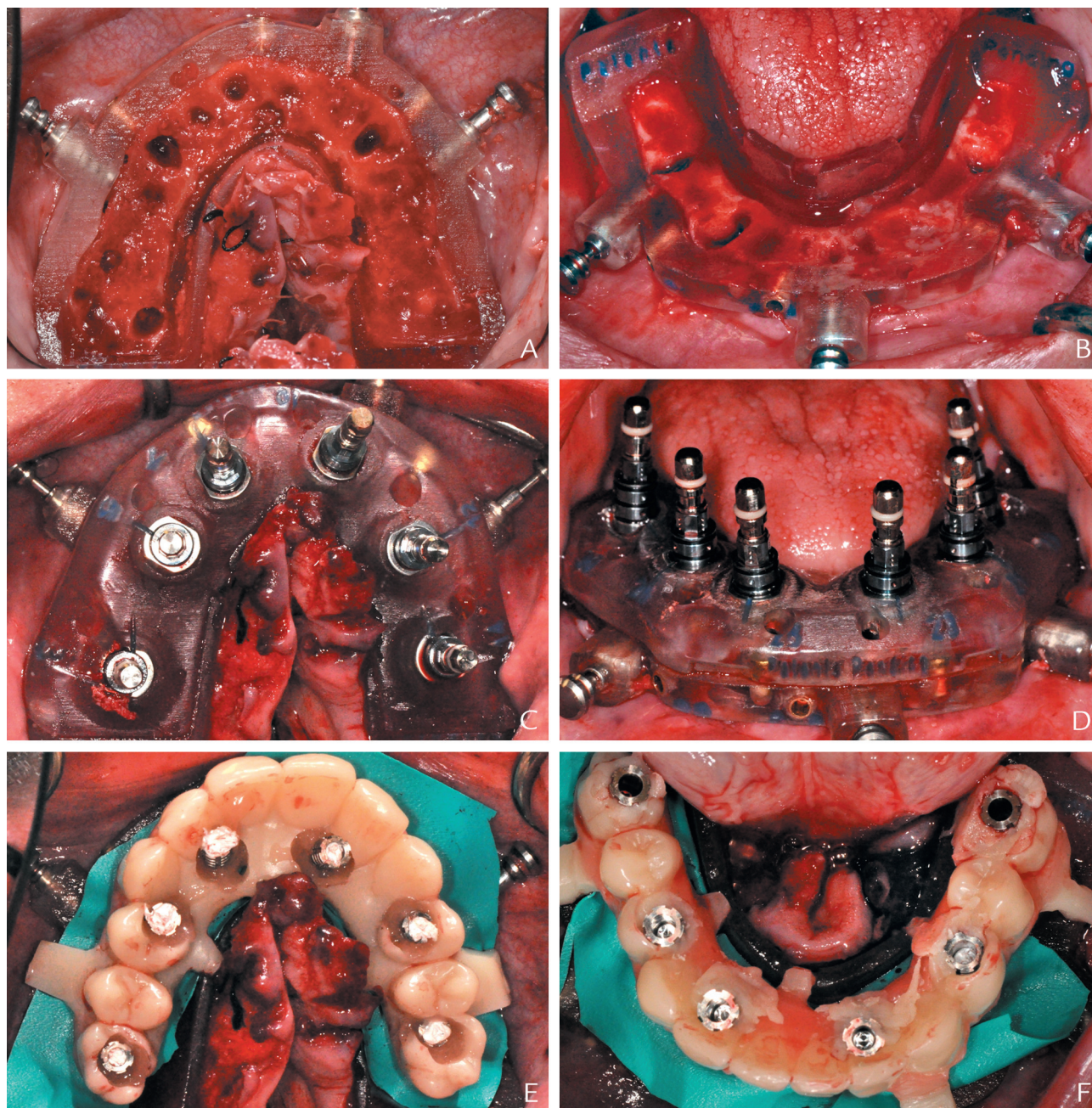
**Figure 6.** CAD/CAM-fabricated edentulous jaw casts and 2-piece surgical templates. A, Maxillary assembly. B, Mandibular assembly. CAD/CAM, computer-aided design/computer-aided manufacture.

planning software (Maven Pro; nSequence). Bone reductions were simulated on the merged file to provide a minimal restorative space of 14 mm between the plane of simulated bone reductions and the antagonist occlusal plane on the virtual diagnostic tooth arrangement for the future planned prostheses.<sup>31,32</sup>

A surgical plan (Fig. 3) was formulated for computer-guided implantation surgery, and a proprietary CAD/CAM design and methodology (Center for Advanced Dentistry; nSequence) was used for the 2-piece surgical templates (CT Guided Surgery; nSequence); this included a bone reduction template with lateral fixation pin access and an implant placement template (Fig. 4). The approved surgical plan was used to refine the virtual diagnostic tooth arrangement in a CAD/CAM software (Zirkonzahn Prettau Element; Zirkonzahn) (Fig. 5A). The definitive virtual diagnostic tooth arrangement was then retrofitted to the virtual bone reduction templates to create CAD/CAM-fabricated interim prosthesis templates (with vertical stops designed and fitted on bone reduction templates) (Figs. 5B-D). Templates for the interim prostheses were milled with the acrylic resin block (Temp Basic; Zirkonzahn, and Milling Unit M5; Zirkonzahn) and layered with light-polymerizing pink composite resin (Gradia Gingival Shade System; GC America Inc) to simulate the desired soft tissue contour and shade.

CAD/CAM-fabricated, maxillary and mandibular edentulous jaw casts (CT Guided Surgery; nSequence), 2-piece surgical templates (CT Guided Surgery; nSequence), and templates for the interim prostheses were returned to the clinicians for presurgery evaluation (Fig. 6). The remaining teeth were extracted and extraction sockets debrided with the patient under local anesthesia and intravenous sedation. With the full-thickness flaps raised, the bone reduction templates were fitted on the alveolar ridges and fixed with anchor pins (Guided Anchor Pin; Nobel Biocare). Planned

osseous recontouring was completed by using bone reduction templates (Figs. 7A, B). The implant placement templates were connected to the bone reduction templates. Six implants (guided 4.1- $\times$ 10-mm, 4.1- $\times$ 8-mm, and 3.3- $\times$ 12-mm; Straumann Bone Level; SLActive; Institut Straumann AG) in each edentulous jaw were placed with the guidance provided by the implant placement templates, with a predetermined insertion torque of 35 to 45 Ncm (Figs. 7C, D). Definitive abutments (regular crossfit/narrow crossfit screw-retained abutment, straight 0° and angled 17°; dimension, 4.6 mm; gingival height, 2.5 mm; Institut Straumann AG) were connected to the implants with a torque of 35 Ncm, and interim titanium copings (NC/RC copings for screw-retained abutment [Ti, Bridge]; D, 4.6 mm; Institut Straumann AG) were connected to the definitive abutments with a torque of 15 Ncm. Templates for the interim prostheses were seated on the bone reduction templates, and autopolymerizing acrylic resin (Jet Tooth Shade Acrylic; Lang Dental) was used to connect them to the provisional titanium copings. Rubber dam protected the surgical sites (Figs. 7E, F). Templates for the interim prostheses and provisional titanium copings were then removed from the abutments. The anchor pins (Guided Anchor Pin) and the bone reduction templates were removed from the alveolar ridges, and the flaps were coronally repositioned with primary closure. The implant-supported interim complete fixed dental prostheses were finished and polished in the laboratory and secured to the definitive abutments with 15 Ncm torque. All screw access was sealed with cotton pellets and single-component resin sealing material (Fermi; Ivoclar Vivadent). A panoramic radiograph of implants was made for post-treatment assessment (Fig. 8). The patient was instructed in a homecare regimen, including a soft diet and 0.12% chlorhexidine gluconate mouthwash (CHG Oral Rinse; Xtrium Laboratories), and was scheduled for periodic follow-up



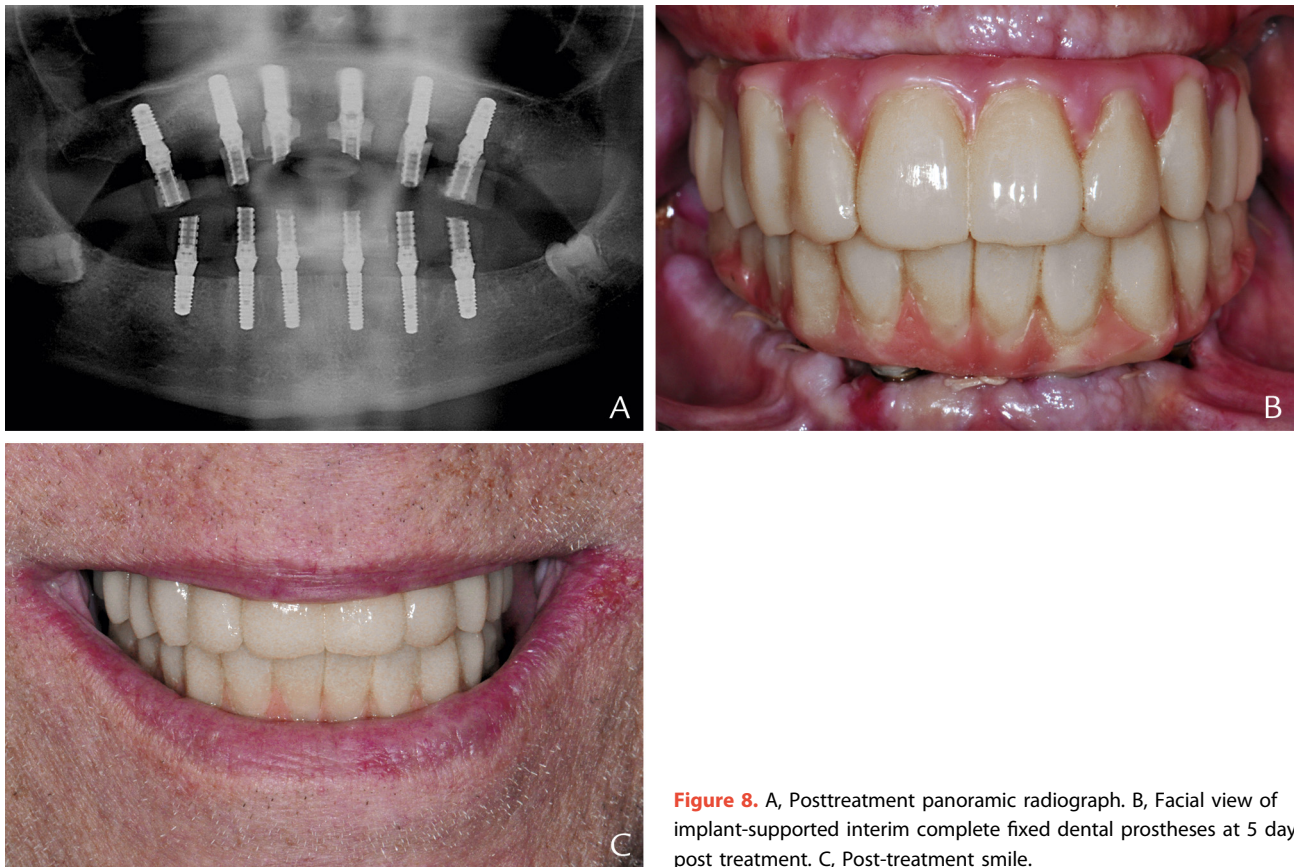
**Figure 7.** Computer-guided surgery and immediate loading procedures. Maxillary osseous recontouring (A) and mandibular osseous recontouring (B) were facilitated by using bone reduction template. Maxillary (C) and mandibular (D) implants were placed with an implant placement template. Conversion of maxillary (E) and mandibular (F) milled interim prosthesis templates to implant-supported interim complete fixed dental prostheses.

appointments. Uneventful healing was observed in the 12 weeks before the definitive impression appointment.

## DISCUSSION

In this clinical report, a contemporary digital pathway was proposed for a patient who presented with minimal remaining restorable teeth and a wish for implant-supported, fixed dental prostheses. The advantages of the

digital pathway were that the diagnostic tooth arrangement was completed virtually and the need for a customized radiographic template was eliminated. Diagnostic data collection required for computer-guided surgery (digital diagnostic impressions, digital photographs, and a CBCT scan) was completed in a single visit with improved workflow efficiency. The virtual implant planning software allowed the digital files (STL files and DICOM files) to be merged in the software for a prosthetically driven



**Figure 8.** A, Posttreatment panoramic radiograph. B, Facial view of implant-supported interim complete fixed dental prostheses at 5 days post treatment. C, Post-treatment smile.

implant surgical plan and the simulated bone reductions to be performed virtually to accurately plan the required restorative space needed for future planned definitive prostheses. The CAD/CAM-fabricated surgical templates, including bone reduction templates with lateral fixation pin access and implant placement templates, allowed the bone reduction templates to be stably positioned throughout the computer-guided surgery, and the immediate loading procedures with improved accuracy. Lastly, the open architecture of the intraoral scanner, CAD/CAM software, and virtual implant planning software enabled the clinician and technician to select the desired design and manufacturing pathway throughout the planning, designing, and manufacturing process.

Some limitations are associated with the proposed workflow. The digital workflow with virtual diagnostic tooth arrangement and the immediate implant placement protocol do not permit a trial insertion, which may limit the esthetic outcome of the implant-supported interim complete fixed dental prostheses. When optimal esthetics or alteration of the vertical dimension of occlusion are necessary, the proposed technique may not be indicated. Milled poly(methyl methacrylate) (PMMA)-based interim prostheses templates were used in this clinical case. Compared with techniques using prosthetic denture teeth,<sup>9,10</sup> the

monochromatic nature of PMMA-based acrylic resin block may impair the esthetics of the interim prostheses. However, layered dentin and enamel acrylic resin may be added to improve the esthetics with additional laboratory expense. The clinicians and dental laboratory technicians require training and experience in the different aspects of dentistry in order to select and operate appropriate CAD/CAM and virtual implant planning software and to perform the proposed clinical procedures.

#### SUMMARY

This clinical report demonstrated treatment with immediate implant placement, computer-guided surgery, and immediately loaded maxillary and mandibular implant-supported interim complete fixed dental prostheses with a contemporary digital approach. All the required diagnostic data were acquired in a single visit, which reduced the overall treatment cost and time for the proposed immediate implant placement, computer-guided surgery, and immediate loading treatments. Milled templates for the interim prostheses were pre-fabricated in a dental laboratory before the computer-guided implantation surgery to facilitate the immediate loading process.

## REFERENCES

1. Gallucci GO, Benic GI, Eckert SE, Papaspyridakos P, Schimmel M, Schrott A, et al. Consensus statements and clinical recommendations for implant loading protocols. *Int J Oral Maxillofac Implants* 2014;29 Suppl: 287-90.
2. Paniz G, Chierico A, Tomasi P, Cuel S. A technique for immediate occlusal implant loading of a completely edentulous mandible: a clinical report. *J Prosthet Dent* 2012;107:221-6.
3. Papaspyridakos P, Chen CJ, Chuang SK, Weber HP. Implant loading protocols for edentulous patients with fixed prostheses: a systematic review and meta-analysis. *Int J Oral Maxillofac Implants* 2014;29 Suppl:256-70.
4. Gallucci GO, Bernard JP, Bertosa M, Belsler UC. Immediate loading with fixed screw-retained provisional restorations in edentulous jaws: the pickup technique. *Int J Oral Maxillofac Implants* 2004;19:524-33.
5. Gallucci GO, Bernard JP, Belsler UC. Treatment of completely edentulous patients with fixed implant-supported restorations: three consecutive cases of simultaneous immediate loading in both maxilla and mandible. *Int J Periodontics Restorative Dent* 2005;25:27-37.
6. Balshi TJ, Wolfinger GJ. Conversion prosthesis: a transitional fixed implant-supported prosthesis for an edentulous arch—a technical note. *Int J Oral Maxillofac Implants* 1996;11:106-11.
7. Yamada K, Hoshina H, Arashiyama T, Arasawa M, Arai Y, Uoshima K, et al. Immediate implant loading following computer-guided surgery. *J Prosthodont Res* 2011;55:262-5.
8. van Steenberghe D, Glauser R, Blombäck U, Andersson M, Schutyser F, Pettersson A, et al. A computed tomographic scan-derived customized surgical template and fixed prosthesis for flapless surgery and immediate loading of implants in fully edentulous maxillae: a prospective multicenter study. *Clin Implant Dent Relat Res* 2005;(suppl 1):S111-20.
9. Bedrossian E. Laboratory and prosthetic considerations in computer-guided surgery and immediate loading. *J Oral Maxillofac Surg* 2007;65(suppl 1):47-52.
10. Lopes A, Maló P, de Araújo Nobre M, Sanchez-Fernández E. The Nobel-Guide All-on-4 treatment concept for rehabilitation of edentulous jaws: a prospective report on medium- and long-term outcomes. *Clin Implant Dent Relat Res*. 5 September 2014. <http://dx.doi.org/10.1111/cid.12260>. [Epub ahead of print].
11. Jensen OT. Complete arch site classification for All-on-4 immediate function. *J Prosthet Dent* 2014;112:741-51.
12. Patzelt SB, Bahat O, Reynolds MA, Strub JR. The All-on-4 treatment concept: a systematic review. *Clin Implant Dent Relat Res* 2014;16:836-55.
13. Oyama K, Kan JY, Kleinman AS, Runcharassaeng K, Lozada JL, Goodacre CJ. Misfit of implant fixed complete denture following computer-guided surgery. *Int J Oral Maxillofac Implants* 2009;24:124-30.
14. Komiya A, Klinge B, Hultin M. Treatment outcome of immediately loaded implants installed in edentulous jaws following computer-assisted virtual treatment planning and flapless surgery. *Clin Oral Implants Res* 2008;19: 677-85.
15. Schneider D, Marquardt P, Zwahlen M, Jung RE. A systematic review on the accuracy and the clinical outcome of computer-guided template-based implant dentistry. *Clin Oral Implants Res* 2009;20(suppl 4):73-86.
16. Chrcanovic BR, Albrektsson T, Wennerberg A. Dental implants inserted in fresh extraction sockets versus healed sites: A systematic review and meta-analysis. *J Dent* 2015;43:16-41.
17. Pieri F, Aldini NN, Fini M, Corinaldesi G. Immediate occlusal loading of immediately placed implants supporting fixed restorations in completely edentulous arches: a 1-year prospective pilot study. *J Periodontol* 2009;80: 411-21.
18. Mozzati M, Arata V, Gallesio G, Mussano F, Carossa S. Immediate post-extraction implant placement with immediate loading for maxillary full-arch rehabilitation: a two-year retrospective analysis. *J Am Dent Assoc* 2012;143: 124-33.
19. Covani U, Orlando B, D'Ambrosio A, Sabattini VB, Barone A. Immediate rehabilitation of completely edentulous jaws with fixed prostheses supported by implants placed into fresh extraction sockets and in healed sites: a 4-year clinical evaluation. *Implant Dent* 2012;21: 272-9.
20. Mozzati M, Arata V, Gallesio G, Mussano F, Carossa S. Immediate post-extractive dental implant placement with immediate loading on four implants for mandibular-full-arch rehabilitation: a retrospective analysis. *Clin Implant Dent Relat Res* 2013;15:332-40.
21. Peñarrocha-Oltra D, Covani U, Aparicio A, Ata-Ali J, Peñarrocha-Diago M, Peñarrocha-Diago M. Immediate versus conventional loading for the maxilla with implants placed into fresh and healed extraction sites to support a full-arch fixed prosthesis: nonrandomized controlled clinical study. *Int J Oral Maxillofac Implants* 2013;28:1116-24.
22. Polizzi G, Cantoni T. Five-year follow-up of immediate fixed restorations of maxillary implants inserted in both fresh extraction and healed sites using the NobelGuide system. *Clin Implant Dent Relat Res* June 2015;17: 221-33.
23. Meloni SM, De Riu G, Pisano M, Dell'avversana Orabona G, Piombino P, Salzano G, et al. Computer-assisted implant surgery and immediate loading in edentulous ridges with dental fresh extraction sockets. Two year results of a prospective case series study. *Eur Rev Med Pharmacol Sci* 2013;17:2968-73.
24. Bornstein MM, Al Nawas B, Kuchler U, Tahmaseb A. Consensus statements and recommended clinical procedures regarding contemporary surgical and radiographic techniques in implant dentistry. *Int J Oral Maxillofac Implants* 2014;29:78-83.
25. Tahmaseb A, Wismeijer D, Coucke W, Derksen W. Computer technology applications in surgical implant dentistry: a systematic review. *Int J Oral Maxillofac Implants* 2014;29 Suppl:25-42.
26. Ting-Shu S, Jian S. Intraoral digital impression technique: a review. *J Prosthodont* 2014 Sep 14. [Epub ahead of print].
27. Mora MA, Chenin DL, Arce RM. Software tools and surgical guides in dental-implant-guided surgery. *Dent Clin North Am* 2014;58:597-626.
28. Scherer MD. Presurgical implant-site assessment and restoratively driven digital planning. *Dent Clin North Am* 2014;58:561-95.
29. Patel N. Integrating three-dimensional digital technologies for comprehensive implant dentistry. *J Am Dent Assoc* 2010;141(suppl 2):205-4S.
30. Stapleton BM, Lin WS, Ntounis A, Harris BT, Morton D. Application of digital diagnostic impression, virtual planning, and computer-guided implant surgery for a CAD/CAM-fabricated, implant-supported fixed dental prosthesis: a clinical report. *J Prosthet Dent* 2014;112:402-8.
31. Sadowsky SJ, Hansen PW. Evidence-based criteria for differential treatment planning of implant restorations for the mandibular edentulous patient. *J Prosthodont* 2014;23:104-11.
32. Sadowsky SJ, Fitzpatrick B, Curtis DA. Evidence-based criteria for differential treatment planning of implant restorations for the maxillary edentulous Patient. *J Prosthodont* 2014 Oct 13. [Epub ahead of print].

**Corresponding author:**

Dr Wei-Shao Lin  
 University of Louisville  
 501 South Preston Street  
 Louisville, KY 40292  
 Email: weiShao.lin@louisville.edu

**Acknowledgments**

The authors thank nSequence, Center for Advanced Dentistry (Reno, Nevada) for assistance in this study.

Copyright © 2015 by the Editorial Council for *The Journal of Prosthetic Dentistry*.