

CLINICAL REPORT

Digital approach to planning computer-guided surgery and immediate provisionalization in a partially edentulous patient

Sirikarn P. Arunyanak, DDS, MS,^a Bryan T. Harris, DMD,^b Gerald T. Grant, DMD, MS,^c Dean Morton, BDS, MS,^d and Wei-Shao Lin, DDS^e

Computer-guided implant surgery has been defined as using a static surgical template to limit the intraoperative modification of implant placement and guide the placement to the preplanned location on the basis of the prosthetically driven surgical plan formulated in the virtual implant planning software.¹ Computer-guided

surgery offers patients the benefits of successful implant placement without flap elevation (flapless surgery) and less postoperative pain and discomfort than with conventional implant surgery.² Although the accuracy of computer-guided surgery has been a concern, with reported mean errors of 0.9 mm at the entry point, 1.3 mm at the implant apex, and a mean angular deviation of 3.5 degrees, the reported implant survival rate of 97% compares with that of conventional implant surgery.³⁻⁵ With the advent of technology, different clinical reports have also shown the potential clinical efficiency of intraoral digital diagnostic scans for virtually planning computer-guided surgery.⁶⁻⁸

Duret et al⁹ are considered the pioneers of dental computer-aided design and computer-aided manufacturing (CAD/CAM), with their development of digital design and fabrication in the early 1970s. Since then, CAD/CAM technology has continued to evolve.¹⁰ CAD/CAM systems consist of 3 basic elements: data

ABSTRACT

This report describes a digital approach for computer-guided surgery and immediate provisionalization in a partially edentulous patient. With diagnostic data obtained from cone-beam computed tomography and intraoral digital diagnostic scans, a digital pathway of virtual diagnostic waxing, a virtual prosthetically driven surgical plan, a computer-aided design and computer-aided manufacturing (CAD/CAM) surgical template, and implant-supported screw-retained interim restorations were realized with various open-architecture CAD/CAM systems. The optional CAD/CAM diagnostic casts with planned implant placement were also additively manufactured to facilitate preoperative inspection of the surgical template and customization of the CAD/CAM-fabricated interim restorations. (*J Prosthet Dent* 2016;■■:■-■)

acquisition with mechanical or optical data capturing/scanning, CAD of the restoration, and CAM of the designed restoration. In the current dental market, many different materials are available for in-office (chairside) and laboratory-based CAD/CAM restorations, including ceramics, polymers, and metal alloys.^{11,12} CAD/CAM systems have also begun to transition from closed to open architecture. Such a change may allow more flexibility in the sources of data acquisitions, a wider selection of digital design software, and more flexibility in terms of digital manufacturing processes and associated restorative materials.¹³ With their increased stability, biocompatibility, and resistance to wear, CAD/CAM high-density polymers have been used to fabricate long-term interim restorations for complex rehabilitations.^{11,14} Furthermore, evidence suggests that the short-term survival rates of CAD/CAM, definitive implant-supported crowns, abutments, and frameworks compare with those that are conventionally fabricated.¹⁵

^aLecturer, Department of Periodontology, Faculty of Dentistry, Chulalongkorn University, Bangkok, Thailand; and Former ITI Scholar, Department of Oral Health and Rehabilitation, School of Dentistry, University of Louisville, Louisville, Ky.

^bAssociate Professor, Department of Oral Health and Rehabilitation, School of Dentistry, University of Louisville, Louisville, Ky.

^cProfessor, Department of Oral Health and Rehabilitation, School of Dentistry, University of Louisville, Louisville, Ky.

^dProfessor, Department of Prosthodontics, School of Dentistry, Indiana University, Indianapolis, In.

^eAssociate Professor, Department of Oral Health and Rehabilitation, School of Dentistry, University of Louisville, Louisville, Ky.

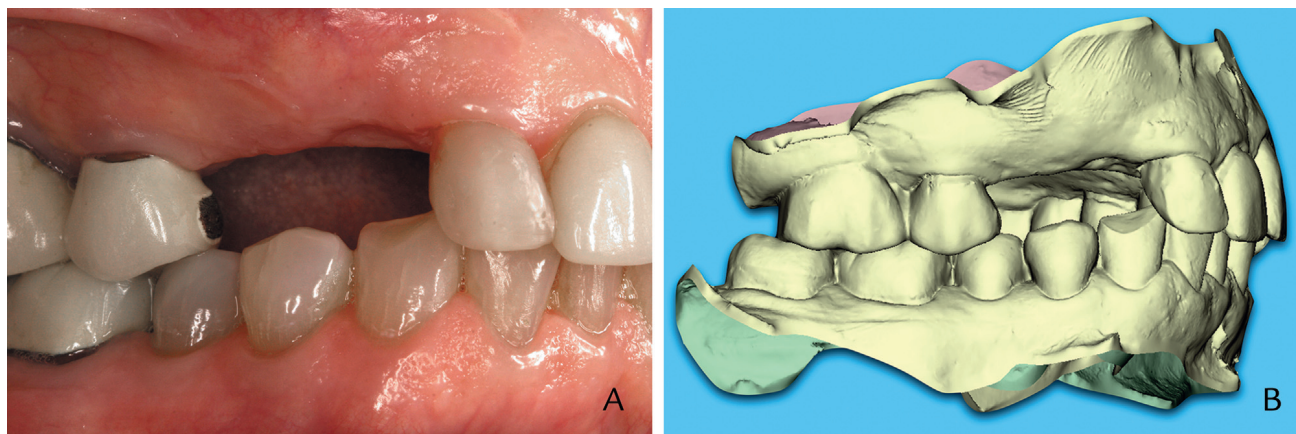


Figure 1. A, Pretreatment condition, buccal view. B, Digital diagnostic scans at maximum incuspation.

Digital intraoral scanners can provide direct intraoral data acquisition and eliminate conventional impressions and stone casts.¹⁶ In combination with CAD/CAM restorations, intraoral scanning has been proposed for various clinical indications, including both fixed and removable dental prostheses on natural dentition and dental implants.^{8,14,17,18} The major limitation of an intraoral scanner is that it does not capture the appropriate soft tissue extension for the conventional tissue-supported removable dental prostheses as well as border molding with conventional impression material.¹⁹ With computer-guided surgery, intraoral scanning allows the clinician to obtain the Standard Tessellation Language (STL) files containing accurate, scatter-free surface representations of both teeth and soft tissue. The STL files can then be imported into the virtual implant planning software and registered with Digital Imaging and Communications in Medicine (DICOM) files generated from cone-beam computed tomographic (CBCT) imaging; this allows clinicians or dental technicians to plan computer-guided surgery.^{20,21}

This report describes a digital pathway for immediate provisionalization with a prosthetically driven plan, computer-guided surgery, and CAD/CAM implant-supported interim restorations.

CLINICAL REPORT

An 80-year-old woman was referred to the Department of Oral Health and Rehabilitation, School of Dentistry, University of Louisville, for the replacement of a missing right maxillary canine and first premolar (Fig. 1A). These teeth had previously been removed and a simultaneous hard tissue augmentation performed in a different clinic. The patient's medical and dental history revealed no significant contraindications for dental treatment. The patient wished to have her missing dentition restored with fixed dental

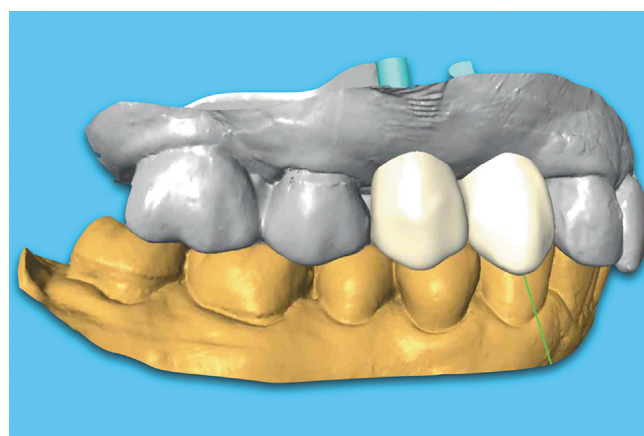


Figure 2. Virtual diagnostic waxing for maxillary canine and first premolar.

prostheses, and the treatment option with 2 dental implants and implant-supported crowns was presented and accepted.

An intraoral digital scanner (Cadent iTero; Align Technology Inc) was used to obtain diagnostic maxillary and mandibular intraoral scans and the interocclusal registration (Fig. 1B). CBCT images (3D Accuitomo170; J. Morita USA) were also obtained for preoperative assessment with a prefabricated universal radiographic template with fiducial markers (Keybite; ProPrecision Guides) for the maxillary dental arch. The approved intraoral scan data were sent to the manufacturer (Cadent iTero; Align Technology Inc) for the proprietary modeling process and for the generation of STL files of virtual diagnostic casts. These files were then imported into laboratory-based CAD/CAM software (Straumann CARES; Straumann USA) to complete the virtual diagnostic waxing (Fig. 2) in a local dental laboratory (Roy Dental Laboratory). New STL files of complete diagnostic waxing were then generated and exported from the CAD/CAM software

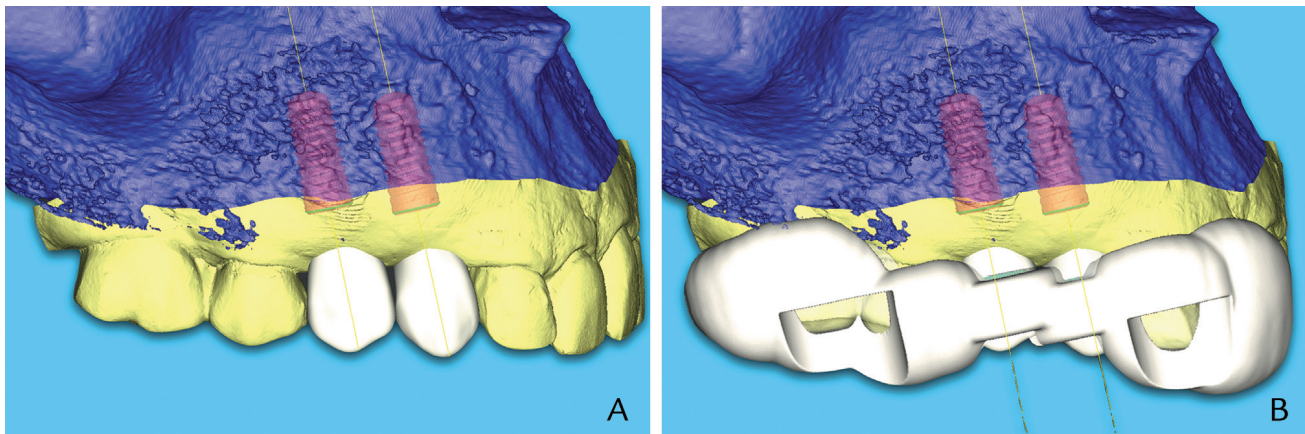


Figure 3. A, Virtual prosthetically driven surgical plan. B, Design of the CAD/CAM surgical template.

(Straumann CARES; Straumann USA) and returned to the clinicians.

All the STL files (virtual diagnostic casts and waxing) and the DICOM files generated from the CBCT imaging were imported and merged in virtual implant planning software (coDiagnostiX; Dental Wings GmbH) in the dental office. A virtual prosthetically driven surgical plan (Fig. 3A) was completed on the basis of the diagnostic information obtained from the intraoral scan, waxing, and CBCT imaging. On the basis of the virtual surgical plan, a CAD/CAM surgical template (Fig. 3B) for subsequent computer-guided implant surgery was also designed in the same virtual implant planning software (coDiagnostiX; Dental Wings GmbH). The clinicians (W.S.L., S.P.A.) transmitted the approved virtual prosthetically driven surgical plan (containing the information of the planned implant locations and timing, virtual diagnostic casts, and CAD of the surgical template) electronically to 2 dental laboratories equipped with the CAD/CAM software and equipment.

The first dental laboratory (ProPrecision Guides) used the approved surgical plan to additively manufacture a CAD/CAM surgical template and diagnostic casts. The complete surgical template and diagnostic casts were sent to the second dental laboratory (Roy Dental Laboratory), which used the approved surgical plan to design the implant-supported, CAD/CAM screw-retained interim restorations in laboratory-based CAD/CAM software (Straumann CARES; Straumann USA) (Fig. 4). The design was then sent to the production facility (Straumann USA) for fabrication with polymethyl methacrylate-based, acrylic resin block (Polycon AE; Straumann USA) and titanium abutments (Variobase; Straumann USA). Upon receipt of the additively manufactured diagnostic casts from the first dental laboratory and the CAD/CAM screw-retained interim restorations from the production center in the

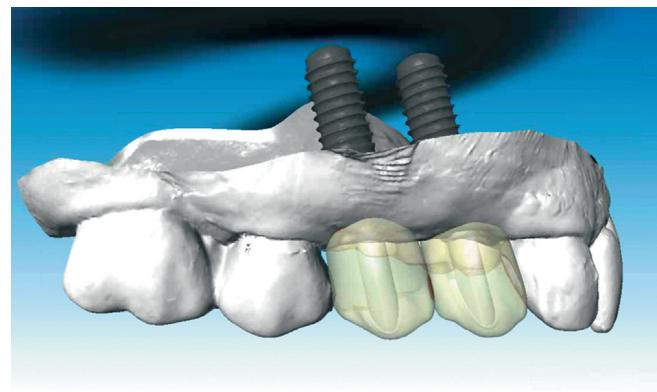


Figure 4. Design of implant-supported, CAD/CAM, screw-retained interim restorations.

second dental laboratory (Roy Dental Laboratory), technicians inserted the implant analogs (RC analog; Straumann USA) into the cast (Fig. 5A) and individualized the facial aspect of CAD/CAM interim restorations with light-polymerizing composite resin (Radica; Dentsply Ceramco) to improve the esthetic results (Fig. 5B). All the completed laboratory products (CAD/CAM surgical template and diagnostic casts and individualized CAD/CAM interim restorations) were then returned to the clinicians.

To prepare for the patient's surgical appointment, the CAD/CAM surgical template was inspected on the additively manufactured diagnostic cast to ensure the complete seating of the template (Fig. 5C), and the approved surgical plan was also printed out to provide the instructions during the computer-guided implant surgery (Fig. 6). The clinical examination revealed that the patient had an adequate amount of keratinized soft tissue at the planned implant area, and the computer-guided implant surgery was performed via a flapless approach. Under local anesthesia, 2 dental implants

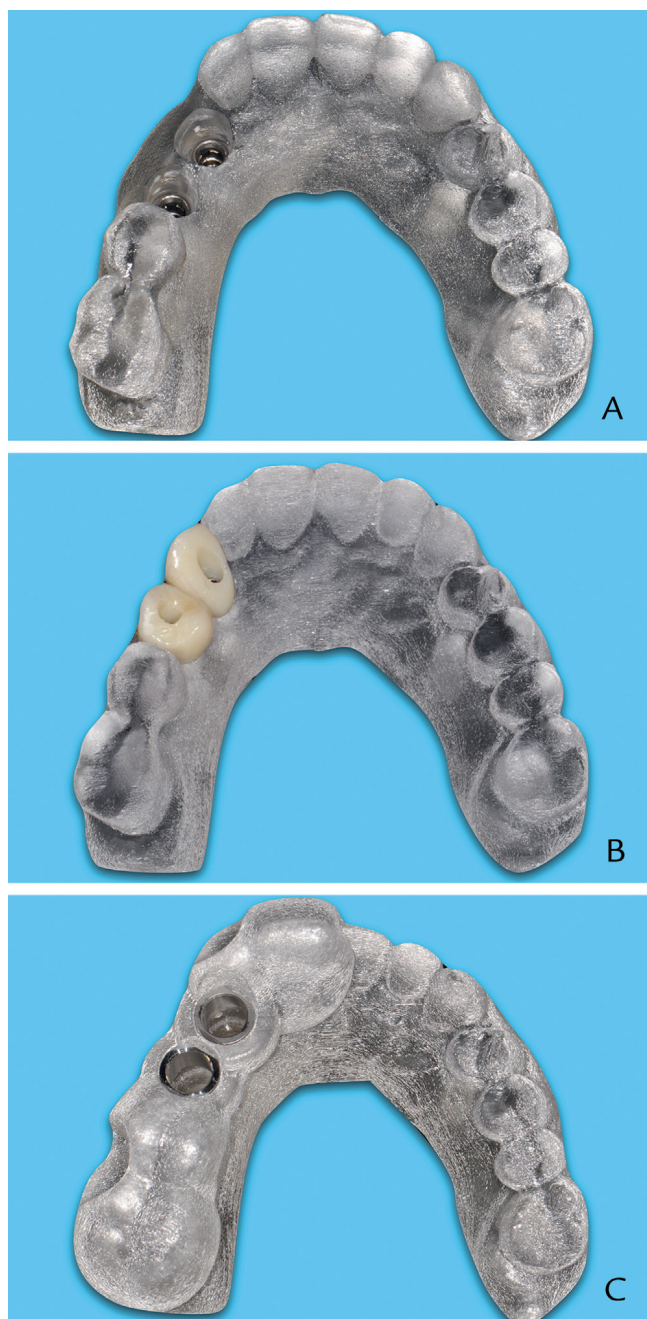


Figure 5. A, Additively manufactured diagnostic cast with implant analogs inserted. B, Individualized CAD/CAM, screw-retained interim restorations. C, CAD/CAM surgical template seated on diagnostic cast.

(Straumann RC, SLActive, guided 4.1 mm × 10 mm; Institute Straumann AG) were placed using the CAD/CAM surgical template (Fig. 7). Primary stability was achieved on the placed implants with an insertion torque of 40 Ncm. After occlusal adjustments to relieve both centric and eccentric occlusal contacts, the CAD/CAM screw-retained interim restorations were secured to the placed dental implants with 20 Ncm torque. The screw accesses in the interim restorations were sealed with cotton pellets and single-component resin sealing

material (Fermit; Ivoclar Vivadent AG) (Fig. 8). The patient was provided with home care instruction and observed for 8 weeks before the definitive impression appointment; healing was uneventful. A summary of the digital workflow used in the clinical and laboratory procedures is presented in Figure 9.

DISCUSSION

Historically, multiple clinical appointments are needed to collect the required diagnostic information for the computer-guided surgery of a patient with partial edentulism. This time-consuming workflow includes obtaining diagnostic impressions, making interocclusal records, fabricating diagnostic casts, performing diagnostic waxing, and obtaining a CBCT scan with a radiographic template. In addition, the interim restoration needed for immediate provisionalization often requires more labor-intensive laboratory procedures before the computer-guided surgery.^{6,8}

With the digital workflow described in this clinical report, the clinician can obtain the required diagnostic information in a single visit, reducing treatment time and cost. The virtual diagnostic waxing and ability of the virtual implant planning software merging all STL and DICOM files eliminate the need to individualize the radiographic template. Furthermore, the CAD/CAM implant-supported, screw-retained interim restorations can be designed and fabricated digitally according to the planned implant placements in the definitive restorative plan. The restoration can be modified in the laboratory to address any further esthetic concerns.

Possible limitations for this proposed workflow are that different CAD/CAM and virtual implant planning software are required in the surgical planning and laboratory process.

The associated cost and system-specific training for this software may increase overall operation cost for both clinicians and dental technicians. With the interchangeability of digital data in the open-architecture software, this clinical report provides a framework of digital workflow. Both clinicians and dental technicians can opt to incorporate different, readily available, compatible digital software from their offices into this digital workflow to reduce the need for new software. Furthermore, for the clinician, the overall cost of acquiring new digital software and the time of surgical planning in the practice can also be reduced when the selected dental laboratory is equipped with compatible CAD/CAM and implant planning software and well-trained dental laboratory technicians.

Although the optional additively manufactured diagnostic cast may increase the treatment cost, these casts

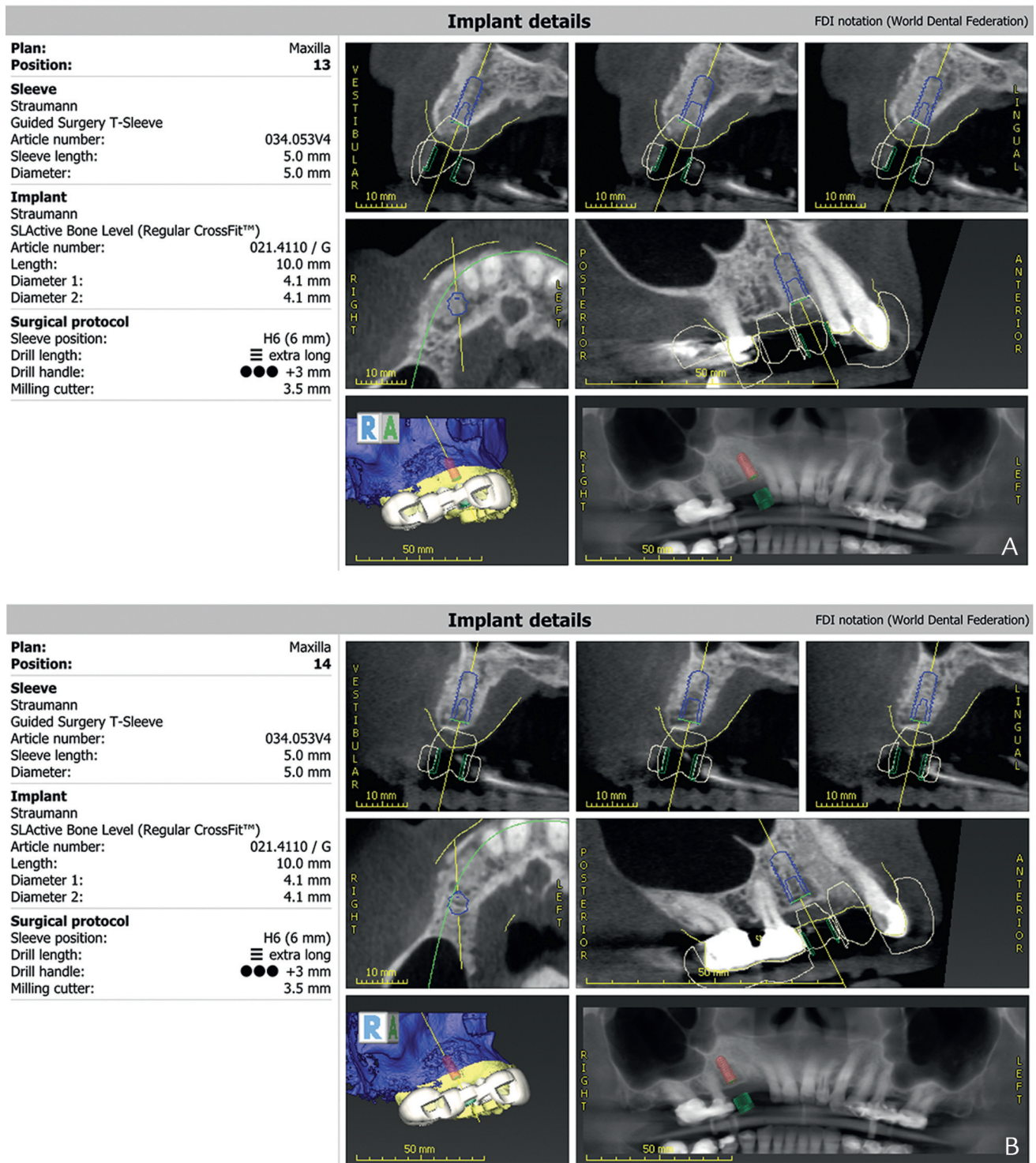


Figure 6. A, Detailed prosthetically driven surgical plan for right maxillary canine. B, Detailed prosthetically driven surgical plan for right maxillary first premolar.

provide the dental technician with the opportunity of individualizing the CAD/CAM interim restorations to enhance the esthetic outcomes and to inspect the CAD/CAM surgical template and individualized interim

restorations before surgery. With experience, this additively manufactured diagnostic cast may be omitted in the posterior area where the esthetic outcome is less critical.

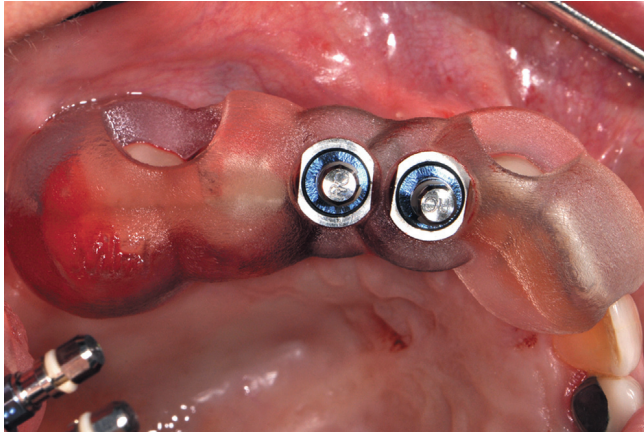


Figure 7. Computer-guided surgery for 2 dental implants completed according to surgical plan with template.

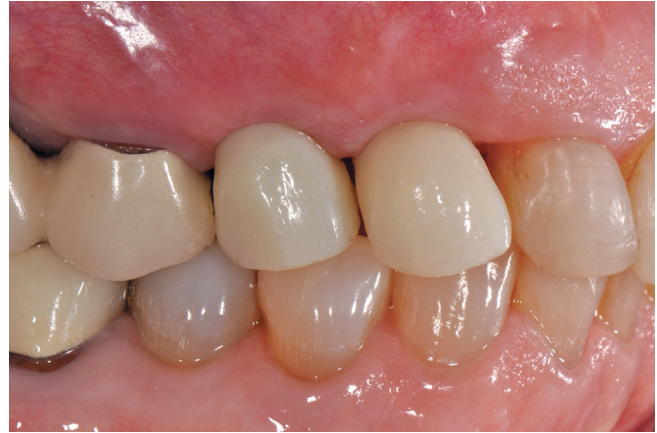

Figure 8. Immediate provisionalization completed with CAD/CAM screw-retained interim restorations.

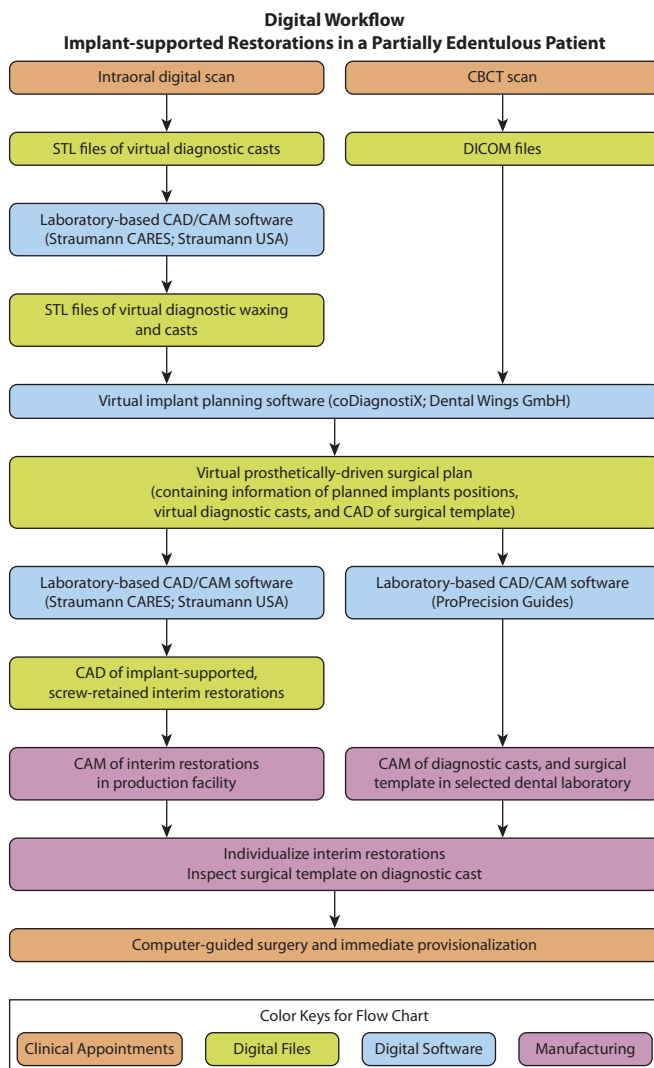


Figure 9. Summarized digital workflow.

SUMMARY

This clinical report described a digital workflow to achieve computer-guided surgery and immediate provisionalization in a partially edentulous patient based on a definitive restorative treatment plan. A single-visit diagnostic data collection approach, a CAD/CAM surgical template, and interim restorations were used to facilitate the successful clinical treatment.

REFERENCES

1. Tahmaseb A, Wismeijer D, Coucke W, Derksen W. Computer technology applications in surgical implant dentistry: a systematic review. *Int J Oral Maxillofac Implants* 2014;29(suppl):25-42.
2. Sicilia A, Botticelli D. Computer-guided implant therapy and soft- and hard-tissue aspects. The Third EAO Consensus Conference 2012. *Clin Oral Implants Res* 2012;23(suppl 6):157-61.
3. D'haese J, Van de velde T, Komiyama A, Hultin M, De bruyin H. Accuracy and complications using computer-designed stereolithographic surgical guides for oral rehabilitation by means of dental implants: a review of the literature. *Clin Implant Dent Relat Res* 2012;14:321-35.
4. Bornstein MM, Al-nawas B, Kuchler U, Tahmaseb A. Consensus statements and recommended clinical procedures regarding contemporary surgical and radiographic techniques in implant dentistry. *Int J Oral Maxillofac Implants* 2014;29(suppl):78-82.
5. Hultin M, Svensson KG, Trulsson M. Clinical advantages of computer-guided implant placement: a systematic review. *Clin Oral Implants Res* 2012;23(suppl 6):124-35.
6. Sudbrink SD. Computer-guided implant placement with immediate provisionalization: a case report. *J Oral Maxillofac Surg* 2005;63:771-4.
7. Lanis A, Alvarez Del Canto O. The combination of digital surface scanners and cone beam computed tomography technology for guided implant surgery using 3Shape implant studio software: a case history report. *Int J Prosthodont* 2015;28:169-78.
8. Stapleton BM, Lin WS, Ntounis A, Harris BT, Morton D. Application of digital diagnostic impression, virtual planning, and computer-guided implant surgery for a CAD/CAM-fabricated, implant-supported fixed dental prosthesis: a clinical report. *J Prosthet Dent* 2014;112:402-8.
9. Duret F, Blouin JL, Duret B. CAD-CAM in dentistry. *J Am Dent Assoc* 1988;117:715-20.
10. Miyazaki T, Hotta Y. CAD/CAM systems available for the fabrication of crown and bridge restorations. *Aust Dent J* 2011;56(suppl 1):97-106.
11. Edelhoff D, Beuer F, Schweiger J, Brix O, Stimmelmayer M, Guth JF. CAD/CAM-generated high-density polymer restorations for the

- pretreatment of complex cases: a case report. *Quintessence Int* 2012;43:457-67.
12. Andreiotelli M, Kamposiora P, Papavasiliou G. Digital data management for CAD/CAM technology. An update of current systems. *Eur J Prosthodont Restor Dent* 2013;21:9-15.
 13. van Noort R. The future of dental devices is digital. *Dent Mater* 2012;28:3-12.
 14. Lin WS, Harris BT, Ozdemir E, Morton D. Maxillary rehabilitation with a CAD/CAM-fabricated, long-term interim and anatomic contour definitive prosthesis with a digital workflow: a clinical report. *J Prosthet Dent* 2013;110:1-7.
 15. Kapos T, Evans C. CAD/CAM technology for implant abutments, crowns, and superstructures. *Int J Oral Maxillofac Implants* 2014;29(suppl):117-36.
 16. Ting-Shu S, Jian S. Intraoral digital impression technique: a review. *J Prosthodont* 2015;24:313-21.
 17. Londono J, Abreu A, Baker PS, Furness AR. Fabrication of a definitive obturator from a 3D cast with a chairside digital scanner for a patient with severe gag reflex: a clinical report. *J Prosthet Dent* 2015;114:735-8.
 18. Lin WS, Chou JC, Metz MJ, Harris BT, Morton D. Use of intraoral digital scanning for a CAD/CAM-fabricated milled bar and superstructure framework for an implant-supported, removable complete dental prosthesis. *J Prosthet Dent* 2015;113:509-15.
 19. Kattadiyil MT, Mursic Z, AlRumaih H, Goodacre CJ. Intraoral scanning of hard and soft tissues for partial removable dental prosthesis fabrication. *J Prosthet Dent* 2014;112:444-8.
 20. Scherer MD. Presurgical implant-site assessment and restoratively driven digital planning. *Dent Clin North Am* 2014;58:561-95.
 21. Mora MA, Chenin DL, Arce RM. Software tools and surgical guides in dental-implant-guided surgery. *Dent Clin North Am* 2014;58:597-626.

Corresponding author:

Dr Wei-Shao Lin
University of Louisville
501 South Preston St
Louisville, KY 40292
Email: WeiShao.Lin@Louisville.edu

Copyright © 2016 by the Editorial Council for *The Journal of Prosthetic Dentistry*.