

# Digital Workflow for Virtually Designing and Milling Ceramic Lithium Disilicate Veneers: A Clinical Report

A Zandinejad • WS Lin • M Atarodi  
T Abdel-Azim • MJ Metz • D Morton

## Clinical Relevance

Digital impressions and virtual CAD/CAM design of ceramic veneers may facilitate the implementation of digital dentistry and virtual design as a viable option for all ceramic restorations.

## SUMMARY

**Laminate veneers have been routinely used to restore and enhance the appearance of natural dentition. The traditional pathway for fabricating veneers consisted of making conventional polyvinyl siloxane impressions, producing stone casts, and fabricating final porcelain prostheses on stone dies. Pressed ceramics have successfully been used for laminate veneer fabrication for several years. Recently, digital computer-aided design/com-**

**puter-aided manufacturing scanning has become commercially available to make a digital impression that is sent electronically to a dental laboratory or a chairside milling machine. However, technology has been developed to allow digital data acquisition in conjunction with electronically transmitted data that enables virtual design of restorations and milling at a remote production center.**

**Following the aforementioned workflow will provide the opportunity to fabricate a physical cast-free restoration. This new technique has**

\*Amirali Zandinejad, DDS, MSc, assistant professor, Department of Oral Health and Rehabilitation, School of Dentistry, University of Louisville, Louisville, KY, USA

Wei-Shao Lin, DDS, assistant professor, Department of Oral Health and Rehabilitation, School of Dentistry, University of Louisville, Louisville, KY, USA

Merila Atarodi, DDS, assistant professor, Department of Pediatric Dentistry, School of Dentistry, University of Louisville, Louisville, KY, USA

Tamer Abdel-Azim, DDS, assistant professor, Department of Oral Health and Rehabilitation, School of Dentistry, University of Louisville, Louisville, KY, USA

Michael J. Metz, DMD, MSD, MS, MBA, assistant professor and vice-chair, Department of General Dentistry, School of Dentistry, University of Louisville, Louisville, KY, USA

Dean Morton, BDS, MS, professor and chair, Department of Oral Health and Rehabilitation, School of Dentistry, University of Louisville, Louisville, KY, USA.

\*Corresponding author: 501 S. Preston Street, Room 312, Louisville, KY 40202; e-mail: a0zand01@louisville.edu

DOI: 10.2341/13-291-S

**been reported recently for all-ceramic IPS e.max full-coverage pressed-ceramic restorations. However, laminate veneers are very delicate and technique-sensitive restorations when compared with all-ceramic full-coverage ones made from the same material. Complete digital design and fabrication of multiple consecutive laminate veneers seems to be very challenging. This clinical report presents the digital workflow for the virtual design and fabrication of multiple laminate veneers in a patient for enhancing the esthetics of his maxillary anterior teeth. A step-by-step process is presented with a discussion of the advantages and disadvantages of this novel technique. Additionally, the use of lithium disilicate ceramic as the material of choice and the rationale for such a decision is discussed.**

## INTRODUCTION

Ceramic materials have been used to mimic the appearance of natural teeth in dental restorations for years now. Several materials and fabrication methods are available on the market.<sup>1</sup> The intention of ceramics has been to closely imitate the optical properties of natural teeth while maintaining acceptable biomechanical and biocompatibility characteristics.

Lithium disilicate glass ceramic using a pressed technique and its applications in clinical dentistry were introduced in 1998 by Brodtkin and others.<sup>2</sup> It is composed of 65% lithium disilicate in the form of crystalline structures,<sup>3</sup> which results in relatively strong ceramic<sup>4</sup> with high flexural strength of about 400 MPa, a fracture toughness of 3.3 MPa m<sup>0.5</sup>, and a good translucency. Lithium disilicate glass ceramic can be etched and bonded to both enamel and dentin. A solution of 10% hydrofluoric acid is used to microetch the bonding surface to increase the bond strength.<sup>5</sup> Different clinical applications are suggested for lithium disilicate ceramics including veneers, anterior and posterior single crowns, and anterior fixed dental prostheses.<sup>6</sup>

By definition, porcelain laminate veneers are thin bonded ceramic restorations that restore the facial and part of the proximal surfaces of teeth requiring esthetic restoration.<sup>7</sup> Introduction of the acid-etch technique by Buonocore in 1955 and porcelain etching in 1983 resulted in long-lasting veneers after adhesive bonding.<sup>8,9</sup> According to the published literature, the veneer material with the most clinical data is feldspathic porcelain. However, new research

on ceramics, including hot pressed, is becoming available in the literature. Lithium disilicate glass ceramic has been used for veneers, but there are limited clinical data regarding its outcome.<sup>10</sup> Porcelain laminate veneer preparations have the advantage of being more conservative than full-coverage crowns and can address some of the limitations of metal-ceramic full-coverage restorations, such as superior optics and color control, supragingival margins, and bonding with improved tissue response.<sup>11</sup>

Digital technology is emerging quickly and has introduced many new aspects to contemporary dental practice. Digital impressions have become an alternative to conventional polyvinyl siloxane (PVS) impression techniques and materials. Clinical evaluation of intraoral digital impressions has shown very promising results. It has been claimed that all ceramic crowns fabricated using chairside scanners have superior marginal fit and improved proximal contact points compared with those fabricated using conventional impressions.<sup>12</sup>

Therefore, the purpose of this paper is to present the esthetic outcome of multiple consecutive lithium disilicate ceramic veneers using a digital impression, virtual computer-aided design/computer-aided manufacturing (CAD/CAM) design, and model-free fabrication. Shortcomings of the novel technique will be presented and discussed in this case report.

## CLINICAL REPORT

A 43-year-old healthy man was referred for a restorative consultation. His chief complaint was large clinical diastemas between his maxillary anterior teeth, 7-10 (Figure 1). Also, the patient was not satisfied with the color and shape of his natural teeth. A comprehensive oral examination and a full-mouth radiographic series were completed. It was determined the patient had a low caries risk with no active dental caries or signs of periodontal disease. Medical history was reviewed and revealed no contraindication for elective dental treatment.

Treatment plan options were discussed with the patient to include vital whitening therapy followed by either direct resin-composite bonding or laminate ceramic veneers. After careful consideration by the patient, vital whitening therapy followed by laminate ceramic veneers was selected as the treatment of choice. Minor soft tissue crown lengthening was recommended to the patient before veneer preparations to correct slight tissue asymmetry. The patient

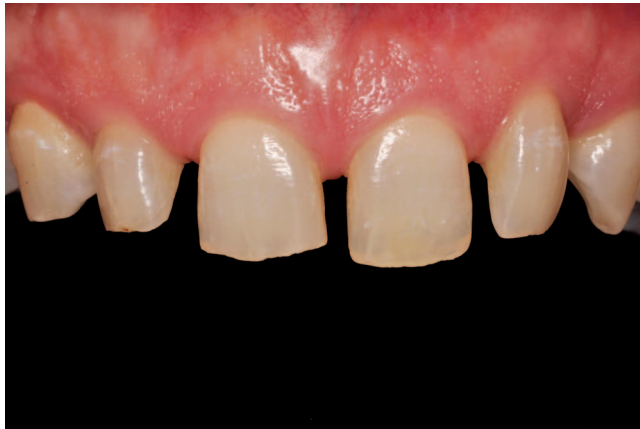

Figure 1. Pretreatment frontal view of maxillary anterior teeth.

declined surgical intervention because he has a low smile line that would not affect the social or esthetic outcomes of his treatment. Vital whitening provides the operator with the opportunity to use a translucent glass ceramic, allowing the stump shade to control the final color. Porcelain laminate veneers are considered a conservative treatment with predictable clinical results.<sup>10,13</sup>

Initial diagnostic impressions were taken for treatment planning using irreversible hydrocolloid impression material (Jeltrate Fast Set, Dentsply Caulk, Milford, DE, USA) and poured with type III dental stone (Buff Stone, Whip Mix Corp, Louisville, KY, USA). Casts were articulated on a semi adjustable articulator (Model 2240, Whip Mix Corp) with a face-bow transfer (Model 8645, Whip Mix Corp). A diagnostic wax-up was completed by the laboratory for patient presentation of proposed shape and contour of final laminate ceramic veneers and provisional stent fabrication (Figure 2).

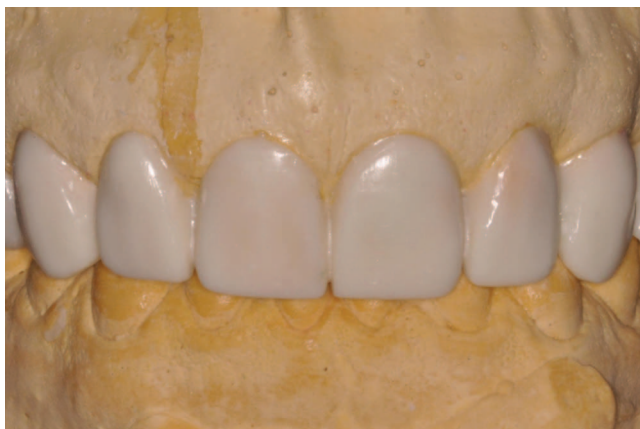

Figure 2. Diagnostic wax-up of maxillary anterior teeth mounted in semiadjustable articulator.

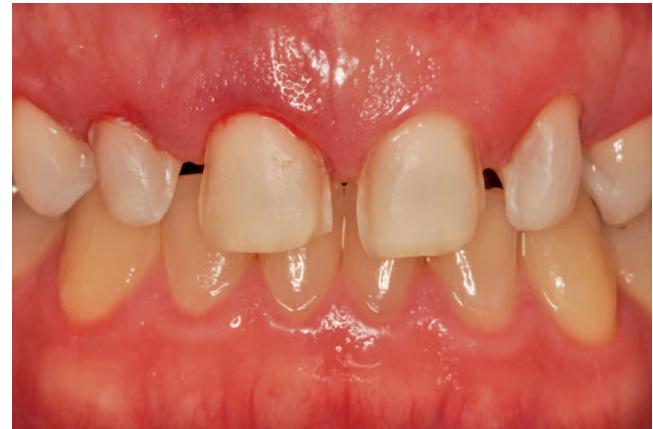

Figure 3. Frontal view of maxillary anterior teeth after preparation for ceramic veneers.

Teeth whitening treatment started with an at-home whitening kit using 15% carbamide peroxide (Opalescence PF 15%, Ultradent Corp, South Jordan, UT, USA) overnight daily for six weeks. The patient's initial tooth shade was Vita A3.5. Preparations were started for laminate ceramic veneers after achieving an acceptable shade (Vita A1) and waiting 14 days post whitening for oxygen free-radical dissipation and possible color regression (Figure 3). The maxillary anterior teeth were prepared with a butt-joint margin on the lingual surfaces, 1.5-mm reduction of the incisal edges and 0.3-mm (gingival) to 0.8-mm (incisal) reduction on facial surfaces using a round-ended diamond cutting instrument (Brasseler USA, Savannah, GA, USA) and a reduction guide (Figure 3).

Soft tissue management and marginal exposure was performed using a single-cord technique (#0 Ultrapak, Ultradent Inc). A CAD digital impression of the prepared maxillary teeth and a CAD digital scan of the opposing mandibular teeth were taken following application of the spray contrast medium (Lava COS, 3M ESPE, St Paul, MN, USA). A closed-jaw record was then taken with the same intraoral digital scanner using the spray contrast media (Figure 4). The CAD software (Lava COS, 3M ESPE) overlapped the digital information obtained from the previously acquired maxillary and mandibular scans with the closed-bite scan to form a virtual bite registration and articulation. The completed CAD data were sent electronically to the scan center at a local commercial dental laboratory to mark the laminate veneer margins and perform a virtual ditching process for marginal design and fabrication (Figure 5). Provisional veneers were virtually designed (Figure 6) using CAD/CAM design software



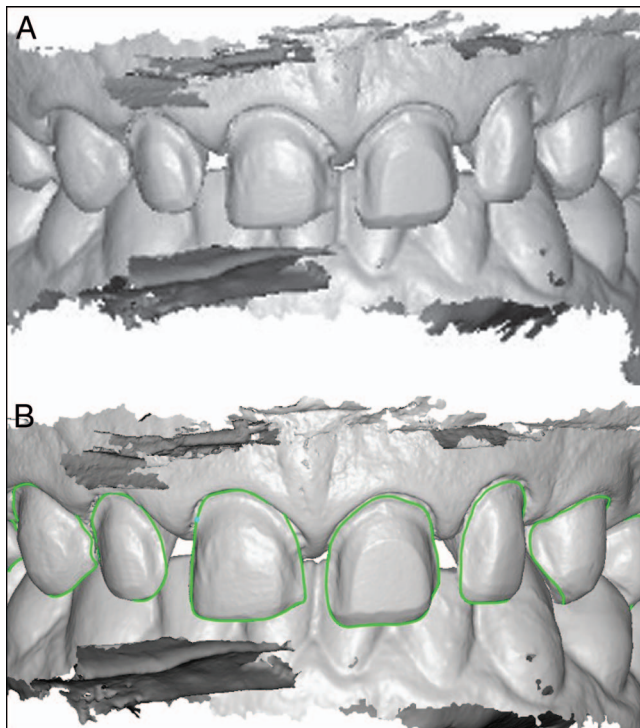


Figure 4. (a): Digital impression and (b): marked finishing margins.

(Dental Wings Inc, Montreal, QC, Canada). The provisional veneers were designed to be splinted for better retention and subsequently milled from poly-methyl-methacrylate (PMMA) Vita A1 blocks within a custom milling center (Figure 7 a,b).

The provisional veneers were tried intraorally for marginal integrity, functionality, occlusion, esthetics, and patient satisfaction. They were temporarily cemented using an acid-etch point technique (midfacial) and bonded with flowable resin composite (Vita A1). Excess composite was removed and polymerized with a VALO Broadband LED Curing Light (Ultra-dent Corp) on standard setting. The occlusion was

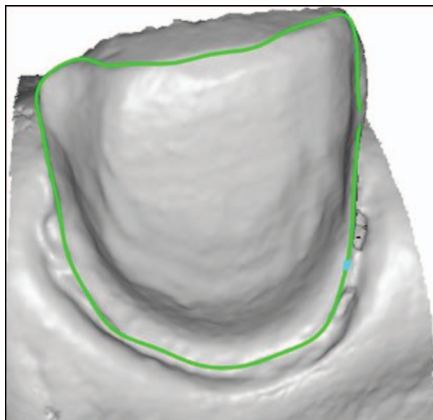


Figure 5. Margin selection and die trim.



Figure 6. Virtual design of connected provisional veneers before milling.

checked and adjusted. The provisional veneers were reevaluated after a few weeks following the patient's evaluation of form, function, and esthetics. The patient requested modifications that were performed and communicated to the dental laboratory. The definitive laminate veneer designs were modified and milled from low translucency IPS e.max (Vita

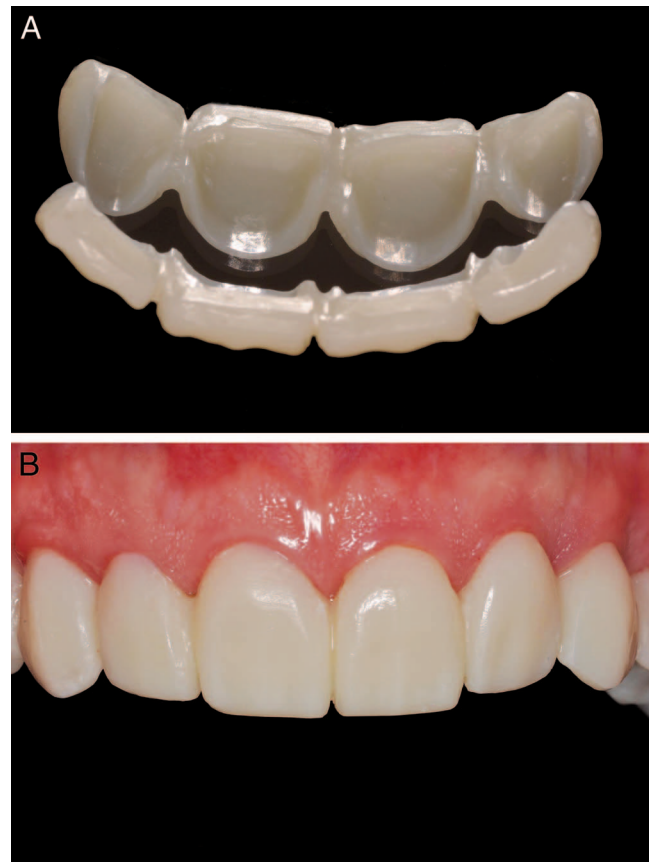

Figure 7. (a): provisional PMMA veneers and (b): PMMA veneers cemented as a long-term provisional.

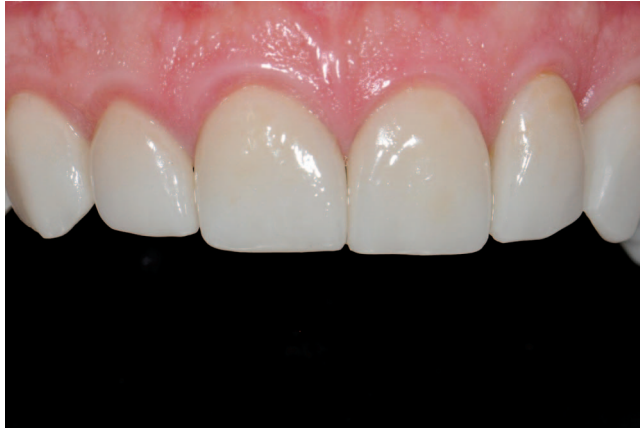

Figure 8. After cementation of lithium disilicate ceramic veneers.

A1) milling blocks (Ivoclar-Vivadent, Amherst, NY, USA) at a remote milling center.

At the insertion appointment, marginal adaptation, restoration fit, interproximal contacts, and occlusion were verified individually and collectively using a translucent try-in paste (RelyX Veneer Kit, 3M ESPE). Minor adjustments to the interproximal contacts were made using a fine diamond bur (Brasseler USA) and were polished using a chairside ceramic polishing kit (Brasseler USA). After final approval by the patient, all internal bonding surfaces of the laminate veneers were etched with 10% hydrofluoric acid for 25 seconds and silanated (Ceramic Silane, 3M ESPE). The laminate veneers were cemented one at a time using a translucent light-cure resin cement (RelyX Veneer, 3M ESPE) following manufacturer recommendations. All excess cement was removed from margins and cured using a VALO Broadband LED Curing Light (Ultradent Corp) on standard setting. The final delivered veneers can be seen in Figure 8.

Upon completion of the bonding process, an irreversible hydrocolloid impression (Jeltrate Fast Set, Dentsply Caulk) was taken of the maxillary arch and poured with type III dental stone (Buff Stone, Whip Mix Corp). The stone model was used to fabricate a vacuum-formed, clear bite guard (Soft-Tray Classic Sheets, 0.08 inches, Ultradent Corp) for nocturnal use by the patient. The patient was instructed on home care and hygiene and was placed on a recall system at six-month intervals. A one-year follow-up was completed.

## DISCUSSION

Laminate veneers have the advantages of being conservative while providing ultimate optical prop-

erties and esthetics. Several techniques and materials have been introduced for fabricating laminate veneers. Upon introduction by Calamia and Horn in 1983, laminate veneers were limited to feldspathic porcelain using the acid-etch technique.<sup>14,15</sup>

Since then, the fabrication techniques and materials have been streamlined by digital dentistry and stronger infiltrated glass ceramics. With the introduction of stronger glass ceramics, especially lithium disilicate pressable glass ceramics, laminate veneers can be fabricated by the lost-wax technique or CAD scanning technology. Due to the emerging CAD scanning technology, complete virtual design (CAD) and milling (CAM) are available.<sup>16,17</sup>

In this clinical case report we designed and fabricated multiple ceramic laminate veneers using a completely digital workflow. The technique chosen provides the opportunity to fabricate precision-milled temporary restorations that represent the proposed final shape, contour, and color of definitive restorations. Long-term provisional restorations can improve the esthetic outcome of the definitive restorations by allowing the patient to critically evaluate them over a period of time.<sup>18</sup> Temporary restorations that were designed and used as long-term interim prostheses provided the opportunity to customize the final restorations further, based on patient feedback, desires, and expectations. There are some disadvantages associated with this technique involving provisional veneer fabrication: the added cost associated with laboratory fabrication, increased chair time, and additional appointments for the patient.

Lithium disilicate glass ceramic was the material of choice in this clinical case. Glass ceramics, especially lithium disilicate, have shown high esthetic potential when treatment planned correctly.<sup>19</sup> The marginal integrity of the milled veneers proved to be clinically adequate. Additionally, the contour, shade, and form of all laminate veneers were all clinically acceptable. However, the breadth and depth of color should be compared with both laboratory hot-pressed and feldspathic ceramic restorations. The aforementioned techniques allow artistic detailing and surface characterization by an experienced laboratory technician or ceramist to provide fine details lacking in CAD design software. The design software used for this cast-free case has minor design limitations for full artistic customization, which may have restricted the esthetic potential of restorations.<sup>16,20</sup> The software does not allow decreasing thickness beyond a certain value that is preset. Furthermore, the shade cannot be

customized prior to fabrication of the restoration. These limitations are software specific and vary by the type of design software used.

Because this is an emerging technology that is constantly being updated, there is a learning curve that involves CAD software developers, clinicians, and dental laboratory technicians. As the dental team members obtain more experience with this innovative technology, additional improvements to the esthetics can be achieved in the near future.

### CONCLUSIONS

This clinical report described a cast-free digital workflow for multiple ceramic veneers. The technique provides the opportunity to enhance the esthetics by using milled acrylic provisional and IPS e.max definitive restorations. All restorations fabricated were clinically acceptable in terms of marginal fit, shape, contour, and esthetics. CAD can be altered to achieve the patients' desires and clinical expectations. Implementation of digital dentistry and virtual design can improve communication among the patient, clinician, and commercial dental laboratories and may become a common technique for all ceramic restorations.

### Conflict of Interest

The authors of this manuscript certify that they have no proprietary, financial, or other personal interest of any nature or kind in any product, service, and/or company that is presented in this article.

(Accepted 17 December 2013)

### REFERENCES

- Anusavice KJ (2003) *Dental Ceramics. Phillips, Science of Dental Materials 12th edition* Elsevier Saunders, St. Louis, MO.
- Brodtkin D, Panzera C, & Panzera P (September 24, 2002) Jeneric/Pentron, Inc. Pressable lithium disilicate glass ceramics US patent 6,455,451 B1
- Albakry M, Guazzato M, & Swain MV (2003) Biaxial flexural strength, elastic moduli, and x-ray diffraction characterization of three pressable all-ceramic materials *Journal of Prosthetic Dentistry* **89**(4) 374-80.
- Höland W, Schweiger M, Frank M, & Rheinberger V (2000) A comparison of the microstructure and properties of the IPS Empress 2 and the IPS Empress glass-ceramics *Journal of Biomedical Material Research* **53**(4) 297-303.
- Guarda GB, Correr AB, Gonçalves LS, Costa AR, Borges GA, Sinhoreti MA, & Correr-Sobrinho L (2013) Effects of surface treatments, thermocycling, and cyclic loading on the bond strength of a resin cement bonded to a lithium disilicate glass ceramic *Operative Dentistry* **38**(2) 208-217.
- Giordano R, & McLaren EA (2010) Ceramics overview: Classification by microstructure and processing methods. *Compendium of Continuing Education in Dentistry* **31**(9) 682-684.
- The glossary of prosthodontic terms (2005) *Journal of Prosthetic Dentistry* **94**(1) 10-92.
- Buonocore MG (1955) A simple method of increasing the adhesion of acrylic filling materials to enamel surfaces *Journal of Dental Research* **34**(6) 849-853.
- Marocho SM, Ozcan M, Amaral R, Bottino MA, & Valandro LF (2013) Effect of resin cement type on the microtensile bond strength to lithium disilicate ceramic and dentin using different test assemblies *Journal of Adhesive Dentistry* **15**(4) 361-368.
- Layton DM, & Clarke M (2013) A systematic review and meta-analysis of the survival of non-feldspathic porcelain veneers over 5 and 10 years *International Journal of Prosthodontics* **26**(2) 111-124.
- Pippin DJ, Mixson JM, & Soldan-Els AP (1995) Clinical evaluation of restored maxillary incisors: Veneers vs PFM crowns *Journal of the American Dental Association* **126**(11) 1523-1529.
- Syrek A, Reich G, Ranftl D, Klein C, Cerny B, & Brodesser J (2010) Clinical evaluation of all-ceramic crowns fabricated from intraoral digital impressions based on the principal of active wavefront sampling *Journal of Dentistry* **38**(7) 553-559.
- Layton DM, & Walton TR (2012) The up to 21-year clinical outcome and survival of feldspathic porcelain veneers: accounting for clustering *International Journal of Prosthodontics* **25**(6) 604-612.
- Calamia JR (1983) Etched porcelain facial veneers: A new treatment modality based on scientific and clinical evidence *New York Journal of Dentistry* **53**(6) 255-259.
- Horn HR (1983) Porcelain laminate veneers bonded to etched enamel *Dental Clinics of North America* **27**(4) 671-684.
- Lin WS, Harris BT, Ozdemir E, & Morton D (2013) Maxillary rehabilitation with a CAD/CAM-fabricated, long-term interim and anatomic contour definitive prosthesis with a digital workflow: A clinical report *Journal of Prosthetic Dentistry* **110**(1) 144-146.
- Fritzsche G (2013) Cerec omnicaam and the virtual articulator—A case report *International Journal of Computerized Dentistry* **16**(1) 59-67.
- Gürel G, & Bichacho N (2006) Permanent diagnostic provisional restorations for predictable results when redesigning the smile *Practical Procedure and Aesthetic Dentistry* **18**(5) 281-286.
- Taskonak B, & Sertgoz A (2006) Two-year clinical evaluation of lithia-disilicate-based all-ceramic crowns and fixed partial dentures *Dental Materials* **22**(11) 1008-1013.
- Beuer F, Schweiger J, Edelhoff D, & Sorensen JA (2011) Reconstruction of esthetics with a digital approach *International Journal of Periodontics and Restorative Dentistry* **31**(2) 185-193.

Queries for odnt-40-03-04

This manuscript/text has been typeset from the submitted material. Please check this proof carefully to make sure there have been no font conversion errors or inadvertent formatting errors. Allen Press.